Laboratorinė medicina.
2018, t. 20, Nr. 2(78), p. 134–138.

Voiding Urosonography in Children

Lina Petronytė[1]
Andrius Čekuolis[2]
Rasa Augustinienė[2]
Augustina Jankauskienė[1]

Summary

Introduction. Urinary tract infections could be the only sign of vesicoureteral reflux (VUR). Vesicoureteral reflux is congenital urinary tract abnormality observed for children. There have not been any studies about methods to diagnose VUR for children by using voiding urosonography (VUS) in Lithuania before.

Material and methods. A total sample of 21 children was investigated from May, 2017 to October, 2017. Nurse catheters the bladder with aseptic rules. *SonoVue* 0.5–1.0 mL is injected into 200–500 mL sodium chloride 9 mg/mL (0.9%). The prepared system is glued up to a height of 40–60 cm. Ultrasound provides images of the bladder, ureters and kidneys, which is performed during filling and voiding of the child bladder. The duration of procedure is around 30–60 minutes. All examinations were recorded and interpreted by the radiologist.

Results. The study involved 8 (38.1%) boys and 13 (61.9%) girls (p=0.5). The average age of children's is 32.05 (±6.84) months. VUR was diagnosed using VUS method in 13 (61.9%) children: 4 boys (30.77%) and 9 girls (69.23%). VUR grade I–II was 7 (53.85%), VUR grade III–V was 6 (46.15%). No acute complications were observed during the study.

Conclusions. Acute severe allergic reactions were not observed in this study. VUS is suitable for the detection or exclusion of VUR and reduces the number of children being exposed to ionizing radiation.

Keywords: children, vesicoureteral reflux, voiding urosonography, *SonoVue*.

INTRODUCTION

Urinary tract infection (UTI) is a serious widespread bacterial infection for children, which might also occur as the first symptom of congenital anomaly of urinary tract. It has been established that around 2% of all boys and 8% of girls will have UTI by the age of seven [1]. This is usually caused by the gram-negative bacteria, with *Escherichia coli* being the most common case (50–90% of all UTIs). Other bacteria, such as *Proteus*, *Klebsiella*, *Enterobacter*, *Enterococcus*, *Staphylococcus*, are observed less frequently [2]. Any delay in diagnosing UTI may result in renal damage.

Urinary tract infections could be the only sign of vesicoureteral reflux (VUR). Previous studies suggest that 25–40% of children with UTI would also have VUR [3]. Vesicoureteral reflux, or retrograde flow of urine from the bladder into the ureter, is congenital urinary tract abnormality observed for children. Despite the exact prevalence of VUR remains unknown, there are some methods to diagnose VUR for children, such as voiding cystourethrography (VCUG), radionuclide cystography (RNC) and voiding urosonography (VUS) [4]. All of these methods require catheterization of the urinary tract. However, according to the clinical practice guidelines of the American Academy of Pediatrics (AAP) released in 2011, VCUG is not recommended after the first occurrence of UTI. Also, VCUG is usually proposed when kidney and bladder ultrasonography reveal hydro-

[1]*Vilniaus universiteto Medicinos fakultetas, M. K. Čiurlionio g. 21, Vilnius, Lietuva*
Institute of Clinical Medicine, Faculty of Medicine, Vilnius University
E-mail: petronyte.lina@gmail.com

[2]*Vaikų ligoninė, Viešosios įstaigos Vilniaus universiteto ligoninės Santaros klinikų filialas Santariškių g. 7, Vilnius, Lietuva*
Children's Hospital, Affiliate of Vilnius University Hospital Santaros Klinikos

nephrosis, parenchymal damage, or other finding that would suggest either high-grade VUR or given some atypical clinical circumstances [5].

VCUG is an invasive procedure with a high risk of irradiation. However, it has long been the golden standard for detecting VUR, so it is really important to select a diagnostic technique that is safe for a child and is approved by parents [6]. As a result, VUS is growing in popularity for the detection of vesicoureteric reflux in hospitals, given its radiation-free methods. Related studies have shown that both VCUG and VUS demonstrate similar sensitivity when detecting vesicoureteral reflux for children [7].

Hence, it is possible to perform two investigations (i.e. VCUG and VUS) in Children's Hospital, Affiliate of Vilnius University Hospital Santaros Klinikos. VUS was first time implemented in Children's Hospital, Affiliate of Vilnius University Hospital Santaros Klinikos in May, 2017. The aim of this investigation was to find out the the usefulness of the method in clinical practice, safety of the VUS and evaluate the satisfaction of parents with this research method.

MATERIAL AND METHODS

A total sample of 21 children was investigated in Children's Hospital, Affiliate of Vilnius University Hospital Santaros Klinikos from May, 2017 to October, 2017. Indications for VUS with *SonoVue* (sulfur hexafluoride) where 1) a boy (<5 years) with the first-time diagnosis of acute pyelonephritis; 2) a girl (<5 years) with the second-time diagnosis of acute pyelonephritis; 3) older children with acute pyelonephritis, suspected having VUR; 4) and follow-up of a previously detected VUR.

Relative contraindications of VUS where 1) acute urinary tract infection; 2) allergy to latex, hypersensitivity to sulfur hexafluoride, or to any of the components of *SonoVue*; 3) urethral injury; 4) recently done urethral or bladder surgery.

SonoVue is the first and only sonographic contrast available in our children's hospital. More specifically, the current ultrasound equipment is Resona 7, Mindray Medical International Ltd., with contrast imaging mode. The mechanical index setting ranged 0.08–0.12.

Before the VUS parents were fully informed about this method and possible complications. The doctor doing the procedure answered all of the parents' questions. Informed written consent was obtained from patients as well.

During the procedure, a patient has to lay down on the bed, while one of the family members is helping by holding child's hands or legs. Then, nurse catheters the bladder with aseptic rules. The catheter is lubricated with vaseline or some other lubricant. If this patient is a newborn or weighs less < 3000 g nurse is using 5 Fr catheter. 6 Fr catheter is usually used for other children < 5 years old, 8 Fr catheter for older patients. A nurse inserts the catheter until the urine appears with additional 2–3 cm. The bladder being emptied of urine and then filled-up with saline. Ultrasound contrast is being prepared according to the manufacturer's instructions. *SonoVue* 0.5–1.0 mL is injected into 200–500 mL 0.9% sodium chloride. The prepared system is glued up to a height of 40–60 cm and the bladder is slowly filled-up with saline – *SonoVue* mix via catheter. Ultrasound provides images of the bladder, ureters and kidneys, which is performed during filling and voiding of the child bladder.

As a result, the healthcare professionals calculate a volume of the bladder and the required solution based on the given formulas below:

< 1 year	1–12 years	>12 years
Weight (kg) × 7 = volume (mL)	(Age + 1) × 30 = volume (mL)	(Age / 2 + 6) × 30 = volume (mL)

The full duration of such procedure is around 30–60 minutes. All examinations were recorded and interpreted by the radiologist.

VUR was classified into five grades following the Classification of International Reflux Study Committee [8].

VUR grade I: reflux into non-dilated ureter.

VUR grade II: reflux into renal pelvis and calyces without dilation.

VUR grade III: reflux with mild to moderate dilation and minimal blunting of fomices.

VUR grade IV: reflux with moderate ureteral tortuosity and dilation of pelvis and calyces.

VUR grade V: reflux with gross dilation of ureter, pelvis, and calyces, loss of papillary impressions, and ureteral tortuosity.

Statistical analysis was performed with SPSS 20.0 and Microsoft Excel packages. Differences are agreed to be statistically significant if p value is lower than 0.05. Results are presented as an average value together with plus/minus standard deviation (±SD).

RESULTS

The study involved 13 (61.9%) girls (p=0.5). The average age of children is 32.05 (±6.84) months. Indications for VUS were 1) a boy (<5 years) with the first-time diagnosis of acute pyelonephritis: 5 (23.81%); 2) a girl (<5 years) with the second-time diag-

Table. **Voiding urosonography results in children**

Patient number	Age (a month)	Finding	Complication
1	13	VUR grade II	None
2	55	VUR not found	None
3	144	VUR not found	None
4	38	VUR grade IV	None
5	38	VUR grade IV	None
6	14	VUR not found	None
7	18	VUR grade II–III	None
8	58	VUR not found	None
9	18	VUR grade II	None
10	44	VUR not found	None
11	7	VUR grade I	None
12	12	VUR grade II	None
13	61	VUR grade I–II	None
14	17	VUR not found	None
15	52	VUR grade III	None
16	12	VUR grade IV	None
17	10	VUR grade I	None
18	25	VUR grade III	None
19	14	VUR grade II	None
20	10	VUR not found	None
21	13	VUR not found	None

nosis of acute pyelonephritis: 8 (38.1%); 3) older children with acute pyelonephritis, suspected having VUR: 1 (4.76%); 4) follow-up of a previously detected VUR: 7 (33.33%).

VUR was diagnosed using the VUS method in 13 (61.9%) children: 4 boys (30.77%) and 9 girls (69.23%). VUR grade I–II was for 7 (53.85%), VUR grade III–V was for 6 (46.15%) (Table). No acute complications were observed during the study. All parents wanted VUS for children with contrast agent *SonoVue*, as opposed to an X-ray contrast study.

DISCUSSION

The results of the study confirm that VUS is an excellent tool for the assessment of VUR. Two-thirds of all children had the diagnosis of VUR confirmed. Some studies have even demonstrated higher sensitivity of VUS when compared to VCUG, especially for high grade VUR. Therefore, the authors propose that VUS should be a method of choice when detecting VUR for pediatric patients [9]. Related literature states that I–III (low/moderate) grades of VURs have a tendency to resolve spontaneously [10]. In clinical practice, it is more important to correctly and timely diagnose a higher degree of VUR, since it could provide an indication for treatment.

Diagnostic techniques, such as voiding cystourethrography or radionuclide cystography, involve radiation exposure for both children and parents. Hence, this is one of the main negative features of these methods. Literature affirms that children are more sensitive to radiation. As they have a longer life expectancy, potentially oncogenic effects of radiation might unfold. Medical radiation can contribute to radiation-induced cancers [11]. The main benefit of VUS is the lack ionising radiation. As a result, VUS is becoming increasingly accepted by children and their parents. Especially, when children require further follow-up.

Another advantage of VUS is related to its dynamic examination. VUS enables doctors to observe of the full process and record the real-time high-quality images (Fig. 1, 2, 3, 4). At the same time, only a few X-rays are available using VCUG. Also, VUR could be missed by using VCUG screening technique. So, there is a higher probability of a false negative diagnosis.

On the other hand, the VUS method has some disadvantages compared to the VCUG. First of all, it requires a longer duration for the examination, which could lead to some serious distress for both children and their family members. For instance, the procedure of VUS lasts from 30 to 60 minutes in our medical centre (including the arrival and the procedure). Therefore, the doctor's workload is high. The research suggests that an incidence of distress occurs in 61–71% of cases during VCUG [12]. Therefore, it is extremely important for health professional to inform family members about the procedure. Another negative feature is related to higher costs of the contrast agent (*SonoVue*) in compari-

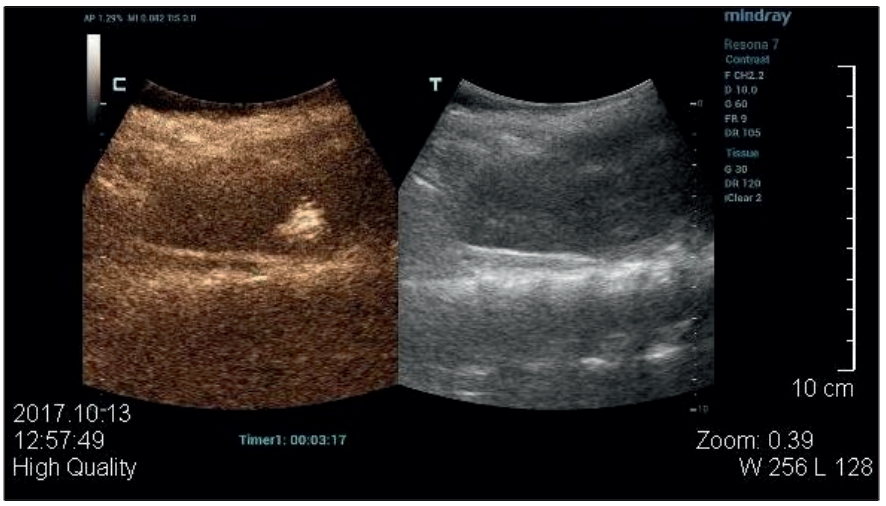

Fig. 1. **VUR III. Residual contrast in the upper right of the right kidney**

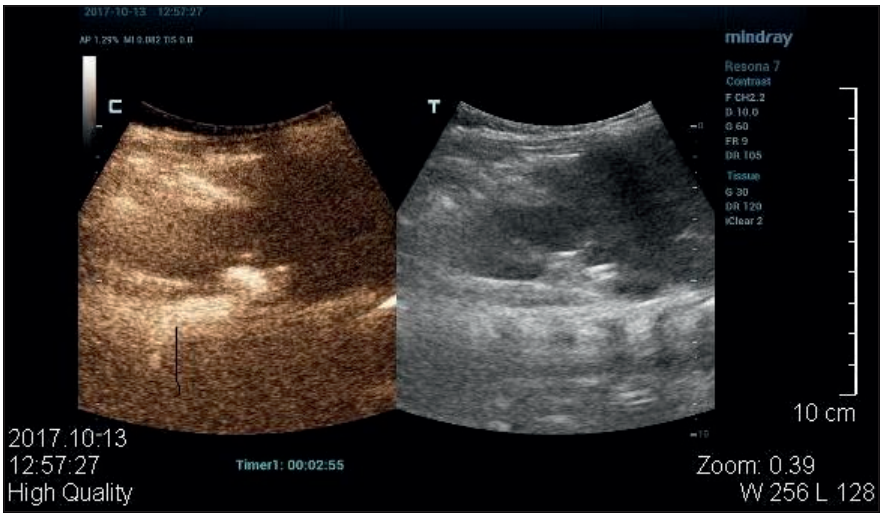

Fig. 2. **VUR III. Wide ureter**

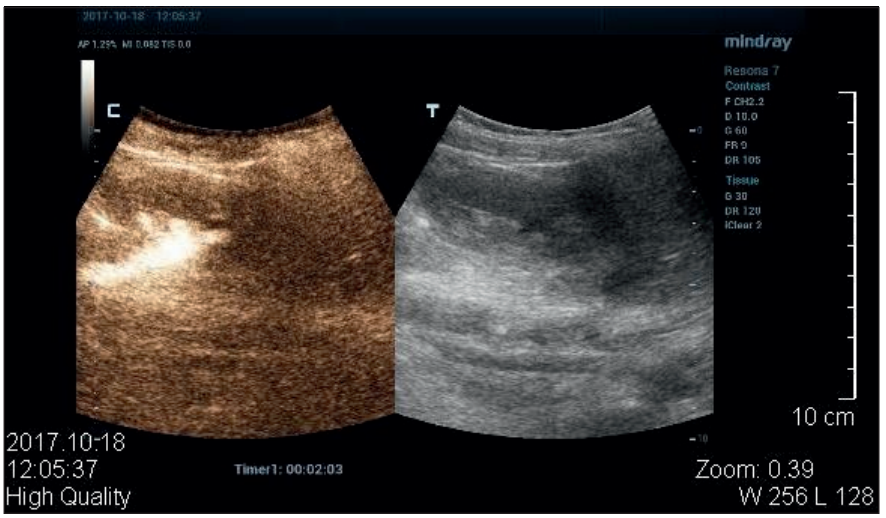

Fig. 3. **VUR IV. Contrast fills the urethra, pelvis, and calyces**

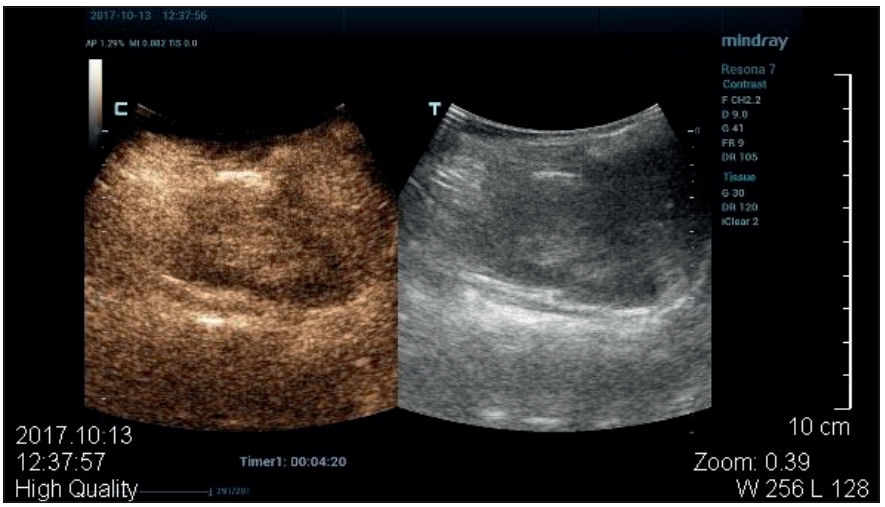

Fig. 4. **VUR not found. Simple contrast image**

son to iodine agents [13]. Also, the medical staff has to be trained to correctly use the contrast agent and have proper skills for interpretation. According to the literature, the technique of VUS remains operator-dependent [14]. Nevertheless, this method of investigation is one of the main tools for diagnosing VUR.

SonoVue is the second-generation ultrasound contrast agent, which is used for ultrasonography of the excretory tract in order to detect vesicoureteral reflux for pediatric patients, starting from newborn to 18 years old. Every millilitre of the dispersion contains 8 l sulphur hexafluoride microbubbles with a phospholipid shell, which have a mean diameter of 2.5 m. Chemical and physical stability of this contrast endures for 6 hours [15]. Moreover, this agent is non-nephrotoxic and could be safely used by children with renal insufficiency [16, 17]. No episodes of acute allergic reaction or complication have been registered to *SonoVue* in our medical centre since May, 2017. This coincides with results of the corresponding study in Greece, where authors assess the safety of *SonoVue* in the population VUS 1010 pediatric patients. The findings of the study do no record any case of serious adverse event. Only a few minor events (3.66%) were reported that was most likely caused by the catheterization. None of the incidents required hospitalization [18]. However, our investigation group is still small, so further continuation is required.

CONCLUSIONS

Acute severe allergic reactions were not observed in this study. VUS is suitable for the detection or exclusion of VUR as well as reduce a number of children being exposed to radiation. ◆

Gauta: 2018 02 26
Priimta spaudai: 2018 06 28

Santrauka

VAIKŲ ULTRAGARSINĖ KONTRASTINĖ CISTOGRAMA

Lina Petronytė, Andrius Čekuolis, Rasa Augustinienė, Augustina Jankauskienė

Įžanga. Šlapimo takų infekcija gali būti vienintelis vezikoureterinio refliukso požymis (VUR). Vezikoureterinis refliuksas yra įgimta vaikų šlapimo takų anomalija. Iki šiol Lietuvoje nebuvo atlikta vaikų VUR diagnostikos naudojant ultragarsinę kontrastinę cistogramą tyrimų.

Medžiaga ir metodai. Nuo 2017 metų gegužės iki 2017 metų spalio tyrime dalyvavo 21 vaikas. Slaugytoja aseptikos sąlygomis kateterizuoja šlapimo pūslę. *SonoVue* 0,5–1,0 ml sumaišoma su 200–500 ml 0,9 % natrio chloridu. Paruošta sistema pakeliama į 40–60 cm aukštį. Užpildant ir ištuštinant vaiko šlapimo pūslę, ultragarso aparatu gaunami šlapimo pūslės, šlapimtakių ir inkstų vaizdai. Procedūros trukmė yra apie 30–60 minučių. Visus tyrimus atlieka ir vertina gydytojas radiologas.

Rezultatai. Tyrime dalyvavo 8 (38,1 %) berniukai ir 13 (61,9 %) mergaičių (p=0,5). Vaikų amžiaus vidurkis – 32,05 ± 6,84 mėn. Ultragarsinės kontrastinės cistogramos metodu VUR buvo diagnozuotas 13 (61,9 %) vaikų: 4 berniukams (30,77 %) ir 9 mergaitėms (69,23 %). I–II laipsnio VUR nustatytas 7 (53,85 %), III–V laipsnio VUR – 6 (46,15 %) vaikams. Tyrimas nesukėlė nė vienos ūminės komplikacijos.

Išvados. Atliekant tyrimą ūminių sunkių alerginių reakcijų nebuvo. Ultragarsinė kontrastinė cistograma yra tinkamas metodas nustatyti ar paneigti VUR, atliekant šį tyrimą išvengiama jonizuojančiosios spinduliuotės.

Reikšminiai žodžiai: vaikai, vezikoureterinis refliuksas, ultragarsinė kontrastinė cistograma, *SonoVue*.

REFERENCES

1. Shaikh N, Morone NE, Bost JE, Farrell MH. Prevalence of urinary tract infection in childhood: A meta-analysis. Pediatr Infect Disease J 2008; 27(4): 302–8.
2. Desai DJ, Gilbert B, McBride CA. Paediatric urinary tract infections: diagnosis and treatment. Aust Fam Physician 2016; 45(8): 558–63.
3. Sorkhi H, Nooreddini H-G, Amiri M, Osia S, Farhadi-Niakee S. Prediction of vesicoureteral reflux in children with first urinary tract infection by dimercaptosuccinic acid and ultrasonography. Iranian Journal of Pediatrics 2012; 22(1): 57–62.
4. Darge K. Voiding urosonography with ultrasound contrast agents for the diagnosis of vesicoureteric reflux in children: I. Procedure. Pediatric Radiology 2008; 38(1): 40–53.
5. Subcommittee on Urinary Tract Infection, Steering Committee on Quality Improvement and Management. Urinary tract infection: clinical practice guideline for the diagnosis and management of the initial UTI in febrile infants and children 2 to 24 months. Pediatrics 2011; 128(3): 595–610.
6. Sorkhi H, Bakhshandeh Bali MK, Nooreddini HG. Randomized clinical trial of sedation with oral midazolam for voiding cystourethrography in children. MJIRI 2010; 24(2): 67–71.
7. Nakamura M, Wang Y, Shigeta K, Shinozaki T, Taniguchi N, Itoh K. Simultaneous voiding cystourethrography and voiding urosonography: an in vitro and in vivo study. Clin Radiol 2002; 57: 846–49.
8. Weiss R, Duckett J, Spitzer A. Results of a randomized clinical trial of medical versus surgical management of infants and children with grades III and IV primary vesicoureteral reflux (United States). The International Reflux Study in Children. J Urol 1992; 148(5 Pt 2): 1667–73.

9. Kis E, Nyitrai A, Várkonyi I, Máttyus I, Cseprekál O, Reusz G, Szabó A. Voiding urosonography with second-generation contrast agent versus voiding cystourethrography. Pediatr Nephrol 2010; 25(11): 2289–93.
10. Smellie JM, Barratt TM, Chantler C, Gordon I, Prescod NP, Ransley PG, et al. Medical versus surgical treatment in children with severe bilateral vesicoureteric reflux and bilateral nephropathy: a randomised trial. Lancet 2001; 357(9265): 1329–33.
11. Perisinakis K, Raissaki M, Damilakis J, Stratakis J, Neratzoulakis J, Gourtsoyiannis N. Fluoroscopy-controlled voiding cystourethrography in infants and children: are the radiation risks trivial? Eur Radiol 2006; 16(4): 846–51.
12. Herd DW. Anxiety in children undergoing VCUG: sedation or no sedation? Advances in Urology 2008; 2008: 498614.
13. Woźniak MM, Pawelec A, Wieczorek AP, Zajączkowska MM, Borzęcka H, Nachulewicz P. 2D/3D/4D contrast-enhanced voiding urosonography in the diagnosis and monitoring of treatment of vesicoureteral reflux in children – can it replace voiding cystourethrography? Journal of Ultrasonography 2013; 13(55): 394–407.
14. Prasad MM, Cheng EY. Radiographic evaluation of children with febrile urinary tract infection: bottom-up, top-down, or none of the above? Advances in Urology 2012; 2012: 716739.
15. Darge K, Papadopoulou F, Ntoulia A, Bulas DI, Coley BD, Fordham LA, et al. Safety of contrast-enhanced ultrasound in children for non-cardiac applications: a review by the Society for Pediatric Radiology (SPR) and the International Contrast Ultrasound Society (ICUS). Pediatr Radiol 2013; 43: 1063–73.
16. Setola SV, Catalano O, Sandomnico F, Siani A. Contrast enhanced sonography in the kidney. Abdom Imaging 2007; 32: 21e8.
17. Detailed information on this medicinal product is available on the website of the European Medicines Agency. http://www.ema.europa.eu/docs/en_GB/document_library/EPAR_-_Product_Information/human/000303/WC500055380.pdf
18. Papadopoulou F, Ntoulia A, Siomou E, Darge K. Contrast-enhanced voiding urosonography with intravesical administration of a second-generation ultrasound contrast agent for diagnosis of vesicoureteral reflux: prospective evaluation of contrast safety in 1,010 children. Pediatr Radiol 2014; 44: 719.